



Arthroscopy-Assisted Fabella Excision: Surgical Technique

Matthew T. Provencher, M.D., George Sanchez, B.S., Márcio B. Ferrari, M.D.,
Gilbert Moatshe, M.D., Jorge Chahla, M.D., Ramesses Akamefula, B.S., and
Robert F. LaPrade, M.D., Ph.D.

Abstract: The fabella is an anatomic variant not seen in all individuals and can potentially be a source of chronic knee pain due to chondromalacia, osteoarthritis, fractures, or biomechanical pressure against the lateral femoral condyle. It is situated intra-articular, close to the lateral femoral condyle, the lateral gastrocnemius head tendon, and the fabellofibular ligament. Given its rarity, the diagnosis of a symptomatic fabella is often overlooked when evaluating patients with persistent posterolateral knee pain. However, this diagnosis should always be considered, especially in high-performance runners, bikers, and triathletes. Although nonoperative management can potentially resolve symptoms associated with this condition, fabella excision via arthroscopically assisted surgery is a reliable and safe alternative to treat patients who do not benefit from nonsurgical treatment. We present our technique detailing fabella excision for treatment of posterolateral knee pain, which includes an arthroscopic evaluation of the fabella to assess damage to the femoral condyle and minimize over-resection and potential damage to surrounding structures.

The fabella is a sesamoid bone located in the posterolateral aspect of the knee, embedded in the muscular and tendon fibers of the lateral head of the gastrocnemius muscle. It articulates anteriorly with the posterior surface of the lateral condyle, and is bordered posteriorly by the oblique popliteal ligament.¹ The presence of the fabella in humans is a variant and is reported to range from 20% to 87%.² When the fabella is present, an additional ligament called the fabellofibular ligament (ligament of Vallois), which runs from the fabella to the fibular head, can be found.²

The presence of the fabella is usually asymptomatic; however, it can be a source of posterolateral knee pain.^{2,3} The pain is usually periodic and is accentuated with the knee in extension, because of the compression of the fabella against the lateral femoral condyle in this position.⁴ Irritation of the common peroneal nerve resulting in neurologic symptoms, such as numbness or pain, may be present in some patients.⁵

Conservative treatment can be an effective way to reduce painful symptoms and increase activities involving extension, flexion, and rotation of the knee.⁶

From the Steadman Philippon Research Institute (M.T.P., G.S., M.B.F., G.M., J.C., R.A., R.F.L.), Vail, Colorado, U.S.A.; The Steadman Clinic (R.F.L.), Vail, Colorado, U.S.A.; Oslo University Hospital and University of Oslo (G.M.), Oslo, Norway; and OSTRC, The Norwegian School of Sports Sciences (G.M.), Oslo, Norway.

The authors report the following potential conflicts of interest or sources of funding: M.T.P. receives consultancy fees from Arthrex and JRF Ortho; has patents issued (9226743, 20150164498, 20150150594, 20110040339); receives royalties from Arthrex and SLACK Incorporated (publishing royalties). G.M. has received research grants from Health South East, Norway, and from Arthrex, not related to this work. R.F.L. receives royalties from Smith & Nephew Endoscopy and Arthrex and is a paid consultant for Smith & Nephew, Ossur Americas, and Arthrex. R.F.L. reports other from Siemens Medical Solutions USA, personal fees and other from Smith & Nephew Endoscopy, personal fees and other from Ossur Americas, other from Small Bone Innovations, personal fees, and other from Arthrex, other from ConMed Linvatec, and other from Opedix, outside the submitted work; has a patent Ossur pending, and a patent Smith & Nephew pending; and is on the editorial/governing board for American Journal of Sports Medicine and

Knee Surgery Sports Traumatology Arthroscopy, and has member/committee appointments with the American Orthopaedic Society for Sports Medicine; International Society of Arthroscopy, Knee Surgery & Orthopaedic Sports Medicine; Arthroscopy Association of North America; and the European Society of Sports Traumatology, Knee Surgery and Arthroscopy. The Steadman Philippon Research Institute has received financial support, not related to this research, from Smith & Nephew Endoscopy, Ossur Americas, Siemens Medical Solutions USA, Small Bone Innovations, ConMed Linvatec, and Opedix.

The investigation was performed at the Steadman Philippon Research Institute, Vail, Colorado, U.S.A.

Received August 12, 2016; accepted October 10, 2016.

Address correspondence to Robert F. LaPrade, M.D., Ph.D., Steadman Philippon Research Institute, 181 West Meadow Drive, Suite 1000, Vail, CO 81657, U.S.A. E-mail: rlaprade@thesteadmanclinic.com

© 2016 by the Arthroscopy Association of North America

2212-6287/16785/\$36.00

<http://dx.doi.org/10.1016/j.eats.2016.10.011>

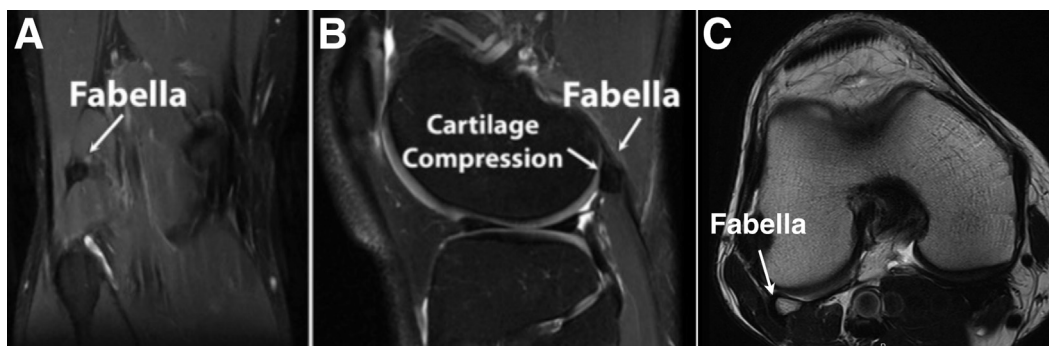


Fig 1. Magnetic resonance imaging (MRI) of a right knee reveals the relationship between the fabella with the lateral femoral condyle and the gastrocnemius tendon in the coronal (A), sagittal (B), and axial (C) views. After a clinical assessment with physical examination, MRI is used to evaluate localized osteoarthritis, cartilage softening and periosteal inflammation of the fabella and femoral condyle.

However, in patients who do not respond to nonoperative treatment, surgical treatment may be performed. A fabella excision can be successfully performed either as an open or arthroscopic procedure.⁷

The aim of this Technical Note is to describe an arthroscopy-assisted fabella excision, which can be challenging because of the position of the fabella to key structures of the posterolateral side of the knee.

Evaluation

The fabella can lead to posterolateral knee pain as a result of focal cartilage damage due to mechanical compression, localized osteoarthritis, cartilage softening, periosteal inflammation, or compressive irritation.^{6,8} Because the fabella is an intra-articular structure with a cartilage lining, this can also degenerate and lead to chronic pain and localized arthritis. Physical examination may reveal the presence of swelling/tenderness in the posterolateral aspect of the knee. A complete knee examination is necessary to evaluate the cruciate ligaments, collateral ligaments, and menisci and exclude other causes of posterolateral pain. Radiographs and sometimes ultrasound are used to confirm the presence of a fabella sesamoid.⁷ Magnetic resonance imaging can be valuable to exclude other causes of knee pain. In addition, magnetic

resonance imaging (Fig 1) may show changes associated with fabella irritation, inflammation, thickening of the lateral gastrocnemius tendon, and evidence of grooving of the articular cartilage on the posterior lateral femoral condyle. Table 1 shows the indications and contraindications for a fabella excision.

Surgical Technique

Preoperative Setup

The patient is placed in a supine position with the surgical limb in a leg holder (Mizuho OSI, Union City, CA). The nonsurgical leg is flexed, abducted, and held in an abduction holder (Birkova Product LLC, Gothenburg, NE) so it does not interfere with the procedure (Video 1). A well-padded thigh tourniquet is placed on the upper thigh of the operative leg. The surgical leg is prepped and draped in a sterile fashion, the leg exsanguinated, and tourniquet inflated. The approach of the fabella is performed prior to fluid extravasation. Table 2 summarizes pearls and pitfalls of fabella excision.

Incision and Exposure

Key superficial landmarks to be marked prior to incision include the Gerdy tubercle, the superficial layer of the iliotibial band, the lateral aspect of the fibular head, and the joint line. Next, a transverse oblique

Table 1. Indications and Contraindications for Fabella Excision

Indications	Contraindications
Symptomatic fabella with pain during knee extension and activities such as running and biking	Patient has not undergone at least 6 months of nonoperative treatment prior to surgery
Compressive forces on the fabella-fibular ligament resulting in posterolateral knee pain	Magnetic resonance imaging findings without clinical symptoms
Compressive irritation of the gastrocnemius tendon resulting in posterolateral knee pain	
Periosteal inflammation due to compression of fabella against the femoral condyle	
Posterior capsule compressed by the fabella	
Compression of nerves between the fabella and fibular head	

Table 2. Pearls and Pitfalls of Fabella Excision

Pearls	Pitfalls
Plain radiographs illustrating this condition are often interpreted as negative; therefore, sonography is usually advised to evaluate localized pain in the knee and allow for more accurate assessment of fabella movement. Moreover, magnetic resonance imaging is important to reveal inflammation within the substance of the lateral gastrocnemius tendon.	Proximity of tendons/structures in the knee must be noted; the lateral (fibular) collateral ligament, popliteus tendon, and lateral head of the gastrocnemius are especially vulnerable to damage during this procedure.
Palpation of the fabella can be safely performed in some patients and should be attempted prior to surgical incision.	Injury to the peroneal nerve during dissection is possible.
Full exposure of the fabella is key to prevent damage of neighboring structures. All structures should be identified before fabella excision. Thorough knowledge of the posterolateral corner anatomy is important. Neurolysis of the common peroneal nerve can be performed in cases with neurologic symptoms.	Given the difficulty in diagnosis of fabella syndrome, it may be overlooked and improperly treated.

incision is performed along the posterior border of the iliotibial band extending from just proximal to the Gerdy tubercle and extending proximally for 8 to 10 cm and centered over the lateral joint line (Fig 2). After blunt retraction of the subcutaneous tissues, the superficial layer of the iliotibial band is incised 1 to 2 cm anterior to its posterior border in the same direction of the fibers (Fig 3). This incision should not be too deep because of the risk of damage to the anterolateral ligament, fibular collateral ligament, and popliteus tendons. Moreover, it is important to refrain from dissection just posterior to the long head of the biceps complex to minimize iatrogenic injury to the peroneal

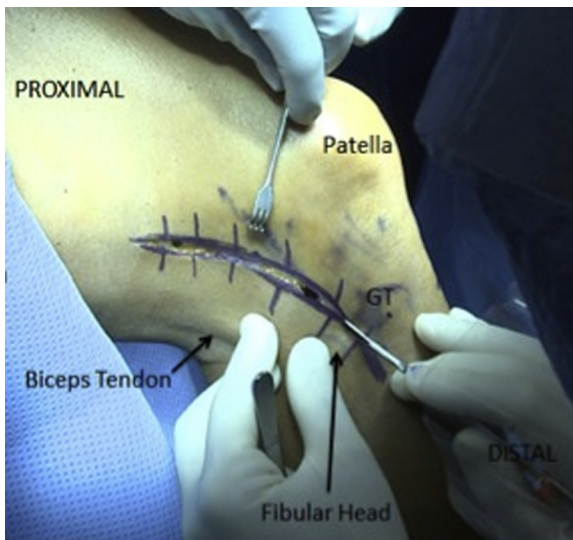


Fig 2. Fabella excision performed in a right knee because of chronic posterolateral pain. The surgical leg is prepped and draped in a sterile fashion. The leg is then exsanguinated while the tourniquet is inflated. The approach of the fabella is performed prior to fluid extravasation with the incision centered over the lateral joint line and spanning along the posterior border of the iliotibial band, from just proximal to the Gerdy tubercle (GT) and extending proximally for 8-10 cm.

nerve. After this, blunt dissection is carried out with scissors anterior to the long head of the biceps femoris through the interval between the lateral gastrocnemius tendon and the fibular collateral ligament aiming distomedial to the fibular head. Next, a blunt dissection can be performed until the desired space has been created to subsequently introduce a Cobb elevator to release any adhesions between the lateral gastrocnemius and the posterolateral capsule.

Fabella Identification by Palpation

The fabella is now identified by palpation at the junction between the lateral head of the gastrocnemius and the posterolateral joint capsule. After identification by palpation, the fabella is secured with an Alice clamp. However, the excision is not performed at this point to minimize fluid extravasation of the joint during arthroscopy.

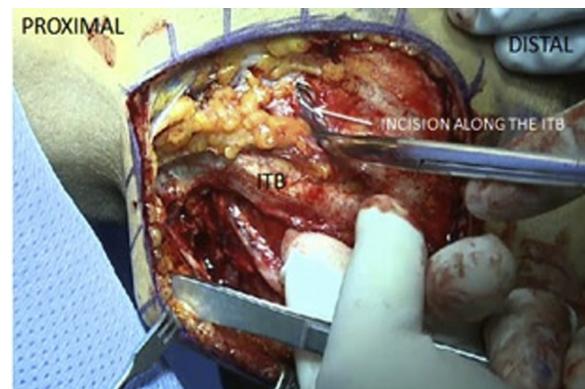

Fig 3. After initial incision, the exposure is continued via an incision performed at 1-2 cm anterior to the posterior border of the iliotibial band (ITB) parallel to the fibers. Blunt dissection is carried out with scissors through the interval between the lateral gastrocnemius tendon and the fibular collateral ligament aiming distomedial to the fibular head. The fabella is identified by palpation at the junction between the lateral head of the gastrocnemius and the posterolateral joint capsule. Of note, care must be taken to avoid damage to the gastrocnemius tendon.

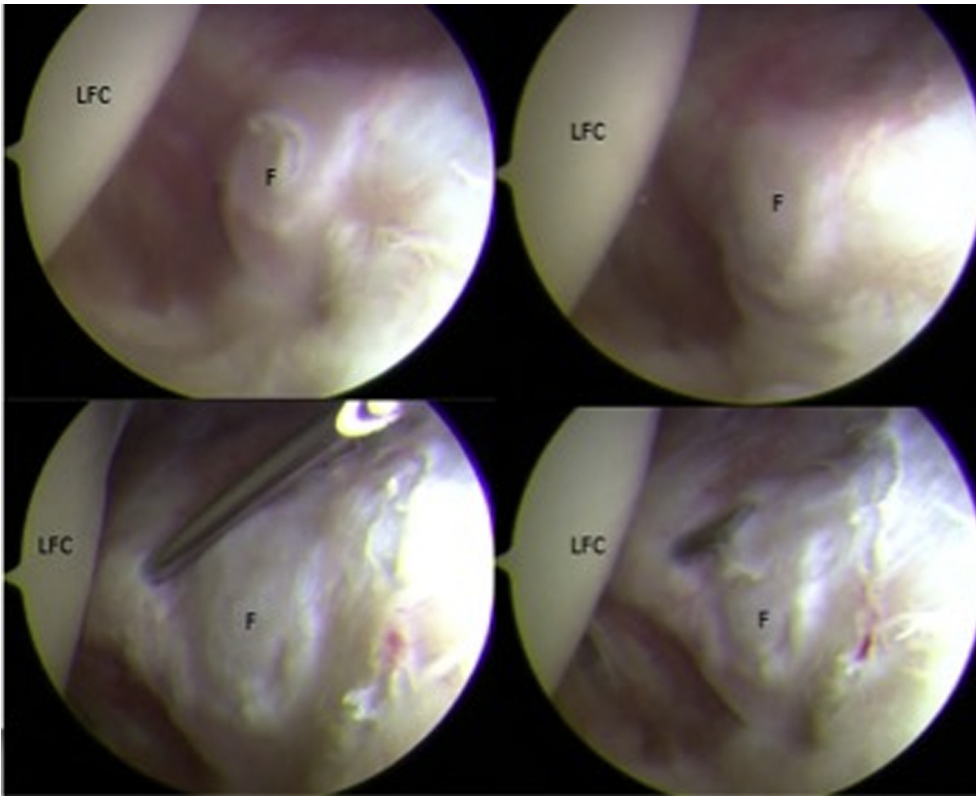


Fig 4. Arthroscopic visualization of the fabella and the surrounding structures performed in a right knee. The arthroscopic portion of the procedure is performed after the open identification of the fabella. A diagnostic arthroscopy is performed in all the compartments to evaluate associated injuries. After this, a needle is used to delimit the margins of the fabella. This allows for proper identification of the fabella and avoids over-resection of the surrounding tissues. (F, fabella; LFC, lateral femoral condyle.)

Knee Arthroscopy and Fabella Excision

After successful identification of the fabella, knee arthroscopy is carried out through standard portals. After a diagnostic arthroscopy, a posterolateral portal is created and a 70° arthroscope (Smith & Nephew, Andover, MA) is inserted to visualize the fabella and verify friction with the posterior aspect of the lateral femoral condyle (Fig 4). After the intra-articular portion of the procedure is finished, careful excision of the fabella is performed under direct visualization

with either a 30° or 70° arthroscope monitoring the capsular incision with the goal of excising it from the lateral gastrocnemius tendon with minimum tissue margins (Fig 5). After successful excision (Fig 6), range of motion is once again assessed to verify an improvement in flexion. Finally, the incisions are closed in a layered fashion. Table 3 summarizes the advantages and disadvantages of arthroscopy-assisted fabella excision.

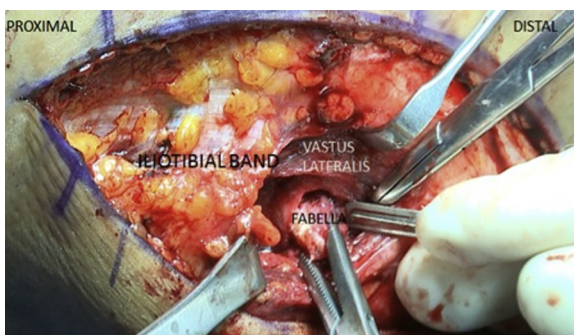

Fig 5. Excision of the fabella performed in a right knee under direct visualization. After the arthroscopic identification of the fabella and evaluation of the surrounding tissues, the excision is performed. Care must be taken to avoid damage to the lateral gastrocnemius tendon, which is in proximity.

Rehabilitation

After an open fabella excision, there is no restriction on range of motion (ROM), and flexion/extension exercises are initiated immediately postoperatively to avoid loss of motion. A brace is not routinely used. The patient is allowed to bear weight as tolerated with the aid of crutches until they can ambulate without a limp. Typically, crutches are necessary during the first 2 weeks postoperatively. However, the use of crutches is at the patient's discretion. Ankle pumps, straight leg raises, and quadriceps exercises are initiated immediately postoperatively as tolerated and frequency gradually increased to 3 to 5 times daily. Return to competitive activities is allowed after approximately 3 to 4 months when the capsule and soft tissues have healed sufficiently.

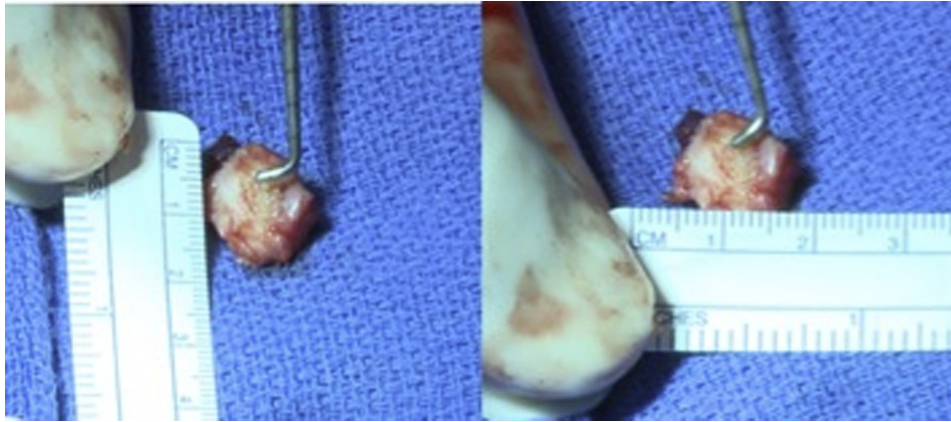


Fig 6. Fabella excision performed in a right knee for treatment of chronic posterolateral knee pain. After the arthroscopic visualization of the fabella along with assessment of damage to the surrounding structures, the fabella is excised. The use of the arthroscopic procedure allows for excision of this sesamoid bone with minimal resection, thereby decreasing the risk of injury to surrounding tissue. Minimal soft tissue resection is shown here with measurements performed with a ruler. Once the fabella has been excised, cartilage damage is evaluated.

Discussion

The fabella, if present, can act as a source of posterolateral knee pain. Therefore, if a patient does present with posterolateral knee pain, careful examination of the knee should rule out a possible symptomatic fabella pressing against the lateral femoral condyle. Previous case reports have described findings of common peroneal neuropathy with foot drop symptoms and a snapping knee syndrome secondary to a symptomatic fabella.^{9,10} Apart from these associated findings, patients also reported increasing pain during aerobic exercise, especially running.¹¹

The treatment of a symptomatic fabella through nonoperative management has been described in several previous case reports.²⁻⁴ Nonoperative treatment centers on steroid injection into the area of maximum palpable discomfort and temporary restriction of activities. In the report detailing the largest number of patients (n = 16) treated for pain resulting from the presence of a fabella, Weiner and Macnab⁴ described treatment outcomes for 11 patients treated operatively and 5 patients treated non-operatively. After an open surgical approach, all 11

patients reported relief of preoperative symptoms with an average follow-up of 22 months. However, of the 5 patients who were treated nonoperatively, 4 complained of periodic pain, including 1 report of significant pain, at an average follow-up of 6.7 months.

Moreover, several case reports show full recovery and relief of all previous symptoms after excision of the fabella.^{6,9} Patel et al.⁹ presented the case of a 67-year-old man with symptoms of pain along the left lower limb as well as common peroneal nerve neuropathy of 18 months’ duration. After open excision of the fabella, this patient had a significant improvement at 3 months with full recovery at 1 year.

Our technique includes an arthroscopic evaluation of the fabella as well as assessment of damage to the femoral condyle, ultimately minimizing damage and over-resection of the surrounding structures during excision of the fabella. Considering these findings as well as the minimal risk of surgical treatment for a symptomatic fabella, we recommend our technique on arthroscopy-assisted fabella excision. Long-term studies with large sample sizes are necessary for further evaluation of this technique and how it

Table 3. Advantages and Disadvantages of Fabella Excision

Advantages	Disadvantages/Risks
An arthroscopy-assisted technique allows for diagnostic arthroscopy that will allow for investigation of other intra-articular causes of posterolateral knee pain. Concomitant intra-articular lesions such as chondral and meniscal lesions can be addressed concurrently.	Proficiency in knee arthroscopy is necessary.
A combination of open surgery and arthroscopy improves the visualization and minimizes the resection of surrounding tissue close to the fabella.	Open surgical approach is very technically demanding, requiring precise surgical dissection and knowledge of the anatomy to avoid ligament and tendon insertions.
With an open approach, the common peroneal nerve can be easily identified and secured, and neurolysis performed, if necessary.	The open procedure may lead to excessive bleeding, compared with arthroscopy-assisted procedures.

compares to nonoperative management. We encourage surgeons to assess the validity of this technique through continued assessment for long-term results.

References

1. Pritchett JW. The incidence of fabellae in osteoarthritis of the knee. *J Bone Joint Surg Am* 1984;66:1379-1380.
2. Driessen A, Balke M, Offerhaus C, et al. The fabella syndrome—a rare cause of posterolateral knee pain: A review of the literature and two case reports. *BMC Musculoskelet Disord* 2014;15:100.
3. Robertson A, Jones SC, Paes R, Chakrabarty G. The fabella: A forgotten source of knee pain? *Knee* 2004;11:243-245.
4. Weiner DS, Macnab I. The “fabella syndrome”: An update. *J Pediatr Orthop* 1982;2:405-408.
5. Mangieri JV. Peroneal-nerve injury from an enlarged fabella. A case report. *J Bone Joint Surg Am* 1973;55:395-397.
6. Zippel JT, Hammer RL, Loubert PV. Treatment of fabella syndrome with manual therapy: A case report. *J Orthop Sports Phys Ther* 2003;33:33-39.
7. Dannawi Z, Khanduja V, Vemulapalli KK, Zammit J, El-Zebdeh M. Arthroscopic excision of the fabella. *J Knee Surg* 2007;20:299-301.
8. Kuur E. Painful fabella. A case report with review of the literature. *Acta Orthop Scand* 1986;57:453-454.
9. Patel A, Singh R, Johnson B, Smith A. Compression neuropathy of the common peroneal nerve by the fabella. *BMJ Case Rep* 2013;2013.
10. Hire JM, Oliver DL, Hubbard RC, Fontaine ML, Bojescul JA. Snapping knee caused by symptomatic fabella in a native knee. *Am J Orthop (Belle Mead NJ)* 2014;43:377-379.
11. Zenteno Chavez B, Morales Chaparro IF, De la Torre IG. Fabella syndrome in a high performance runner. Case presentation and literature review [in Spanish]. *Acta Ortop Mex* 2010;24:264-266.