

Biomechanical Comparison of Screw Fixation Versus a Cortical Button and Self-tensioning Suture for the Latarjet Procedure

Matthew T. Provencher,^{*†} MD, CAPT, MC, USNR, Zachary S. Aman,^{*} BA, Christopher M. LaPrade,^{*} MD, Andrew S. Bernhardtson,^{*†} MD, Gilbert Moatshe,^{*‡§} MD, PhD, Hunter W. Storaci,^{*} MS, Jorge Chahla,^{*} MD, PhD, Travis Lee Turnbull,^{*} PhD, and Robert F. LaPrade,^{*†||} MD, PhD

Investigation performed at the Department of Biomedical Engineering, Steadman Philippon Research Institute, Vail, Colorado, USA

Background: Metal screws are traditionally used to fix the coracoid process to the glenoid. Despite stable fixation, metal screws have been associated with hardware complications. Therefore, some studies have advocated for suture button fixation during the Latarjet procedure to reduce the complications associated with screw fixation.

Purpose: To biomechanically evaluate the ultimate failure load of a cortical button and self-tensioning suture versus metal screws for coracoid graft fixation during the Latarjet procedure.

Study Design: Controlled laboratory study.

Methods: Eight matched pairs of fresh-frozen, male cadaveric shoulders (N = 16) underwent the Latarjet procedure. The shoulders of each pair were randomly assigned to 1 of 2 groups: fixation using two 3.75-mm cannulated, fully threaded metal screws or fixation using a double suture button construct. Specimens were secured in a dynamic testing machine and cyclically preconditioned from 2 to 10 N at 0.1 Hz for 10 cycles. After preconditioning, specimens were pulled to failure at a normalized displacement rate of 400% of the measured gauge length per minute. The ultimate failure load and mechanism of failure were recorded for each specimen.

Results: The mean ultimate load to failure for screw fixation (226 ± 114 N; 95% CI, 147-305 N) was not significantly different from that for suture button fixation (266 ± 73 N; 95% CI, 216-317 N) ($P = .257$). The mean strain at failure for screw fixation (63% ± 21%; 95% CI, 48%-77%) was not significantly different from that for suture button fixation (86% ± 26%; 95% CI, 69%-104%) ($P = .060$). The most common mechanism of failure for the screw fixation method was at the bone block drill holes, while an intramuscular rupture at the clamp-muscle interface occurred for the suture button construct.

Conclusion: The screw and suture button fixation techniques exhibited comparable biomechanical strength for coracoid bone block fixation of the Latarjet procedure.

Clinical Relevance: Metal screws have been reported to be a large contributor to intraoperative and postoperative complications. Therefore, given the results of the current study, a suture button construct may be an alternative to metal screw fixation during the Latarjet procedure. However, further clinical studies are warranted.

Keywords: shoulder; Latarjet; conjoint tendon; anterior shoulder instability; glenoid bone loss

The Latarjet procedure, first described in 1954,¹⁷ involves the transfer of the coracoid process to the anterior glenoid and has been reported to have satisfactory clinical and biomechanical results in terms of restoring anterior stability of the shoulder.^{8,11,12,14,20,24,34} However, systematic reviews have reported that 3% of patients still experience

anterior dislocations and that 3.3% to 7.5% have recurrent humeral head subluxations after the procedure.^{8,12,20}

Metal screws are traditionally used to fix the coracoid process to the glenoid, and screw fixation has been validated through clinical^{2,27} and biomechanical data.^{1,16,32} Despite stable fixation, metal screws have been associated with hardware complications of between 6.5%⁸ and 46%.¹⁸ Therefore, some studies have advocated for suture button fixation during the Latarjet procedure to reduce the complications associated with screw fixation.^{5,9,10} It has been reported that 91% of patients had bone block healing on

The Orthopaedic Journal of Sports Medicine, 6(6), 2325967118777842
DOI: 10.1177/2325967118777842
© The Author(s) 2018

This open-access article is published and distributed under the Creative Commons Attribution - NonCommercial - No Derivatives License (<http://creativecommons.org/licenses/by-nc-nd/4.0/>), which permits the noncommercial use, distribution, and reproduction of the article in any medium, provided the original author and source are credited. You may not alter, transform, or build upon this article without the permission of the Author(s). For reprints and permission queries, please visit SAGE's website at <http://www.sagepub.com/journalsPermissions.nav>.

computed tomography after the Latarjet procedure utilizing suture button fixation at 6 months, with no reported neurological or implant complications at a mean follow-up of 14 months.¹⁰

Nevertheless, biomechanical data comparing screw fixation to suture button fixation for the Latarjet procedure are lacking in the literature. The purpose of the current study was to biomechanically evaluate the ultimate failure load of a suture button construct versus traditional metal screws for coracoid graft fixation during the Latarjet procedure. We hypothesized that there would be no significant difference in the ultimate failure load and mechanism of failure between the 2 fixation techniques.

METHODS

Study Design

Sixteen fresh-frozen, male cadaveric shoulders (8 matched pairs) with a mean age of 55.1 years (range, 35–68 years) and mean body mass index of 28.3 kg/m² (range, 26.4–33.5 kg/m²) were used in this study. Male shoulders were chosen to ensure adequate bone quality and eliminate an extra variable from the analysis (male vs female). Four additional cadaveric shoulders were used for pilot testing before commencing the study. Institutional review board approval was not required because the use of cadaveric specimens is exempt at our institution. The cadaveric specimens utilized in this study were donated to a tissue bank for the purpose of medical research and then purchased by our institution. The shoulders of each pair were randomly assigned to 1 of 2 groups: (1) fixation using two 3.75-mm cannulated, fully threaded metal screws or (2) fixation using a double suture button construct. Two 3.75-mm bicortical cannulated (Arthrex), 3.5-mm cannulated (Mitek), and 4.5-mm solid screws (Synthes) have recently been reported to have comparable maximal displacement in a biomechanical study³¹; therefore, 3.75-mm screws were chosen for this study.

Specimen Preparation

The shoulders were dissected beginning with a deltopectoral approach to identify the coracoid process and conjoint tendon of the short head of the biceps brachii and coracobrachialis at its origin on the tip of the coracoid process. The pectoralis minor was reflected off the coracoid process medially. The coracoacromial ligament was subsequently sectioned at its coracoid attachment. An oscillating saw was

used to perform osteotomy 23 mm proximal to the anterior tip of the coracoid process with the conjoint tendon left attached. The inferior edge of the coracoid was decorticated in a standard fashion. A subscapularis split was created sharply along its fibers from the insertion of the subscapularis tendon to the musculotendinous junction to facilitate exposure of the glenoid.²² The subscapularis split was performed to replicate the clinical setting as much as possible. To simulate a glenoid defect of critical size for anterior instability,^{32,33} a 6-mm defect was planned and measured from the 3-o'clock position of the glenoid, and a cut was made parallel to the long axis of the glenoid with an oscillating saw. For both groups, the procedures were performed by a sports medicine fellowship-trained orthopaedic surgeon (A.S.B.).

For the screw fixation group, the coracoid bone block was fixed into place using two 3.75-mm cannulated, fully threaded titanium metal screws with washers (Arthrex) (Figure 1A). The screws were compressed to 2-finger tightness and subjectively observed to achieve adequate fixation as experienced clinically by the orthopaedic surgeon (A.S.B.). For the suture button fixation group (Knotless AC Repair System; Arthrex) (Figure 1B), the procedure was first performed by introducing two 3-mm cannulated drills (Arthrex) through a custom guide (10 mm apart) and advanced with power through the graft and the anterior glenoid neck under direct vision. The guide was then removed, and the central cores of the cannulated drills were unscrewed. Retrieval sutures (FiberStick; Arthrex) were passed through the cannulated drills and retrieved from the anterior holes. The drills were removed, and the retrieval sutures were used to shuttle the suture button construct from posterior to anterior. Both suture button sutures were then retrieved and passed through the corresponding hole of the coracoid graft. A surgical button (Dog Bone Button; Arthrex) was attached to the 2 loops of each self-tensioning suture. Finally, the self-tightening sutures were progressively tensioned such that the round posterior buttons of the construct were positioned flush on the cortex of the posterior glenoid neck.

To implement consistent compression of the graft on the anterior glenoid, 267 N (60 lb)⁵ of tension was applied sequentially to each suture strand with a suture tensioner from posteriorly, securing the Dog Bone Button to the anterior surface of the coracoid graft, and each tight rope was secured with a surgeon's knot and 6 alternating half-hitches. Two cortical button and self-tensioning suture constructs were utilized to limit the variability in holes

||Address correspondence to Robert F. LaPrade, MD, PhD, Steadman Philippon Research Institute, 181 West Meadow Drive, Suite 1000, Vail, CO 81657, USA (email: rlaprade@thesteadmanclinic.com).

*Steadman Philippon Research Institute, Vail, Colorado, USA.

†The Steadman Clinic, Vail, Colorado, USA.

‡Oslo University Hospital, Oslo, Norway.

§OSTRC, Norwegian School of Sports Sciences, Oslo, Norway.

One or more of the authors has declared the following potential conflict of interest or source of funding: This study was partially supported by Arthrex and internally by the Steadman Philippon Research Institute. M.T.P. is a paid consultant for Arthrex and the Joint Restoration Foundation (AlloSource) and receives royalties from Arthrex and SLACK. A.S.B. has received financial/material support from Smith & Nephew. R.F.L. is a consultant for Arthrex, Ossur, and Smith & Nephew; receives royalties from Arthrex, Ossur, and Smith & Nephew; and receives research support from Arthrex, Ossur, Linvatec, and Smith & Nephew.

Ethical approval was not sought for the present study.

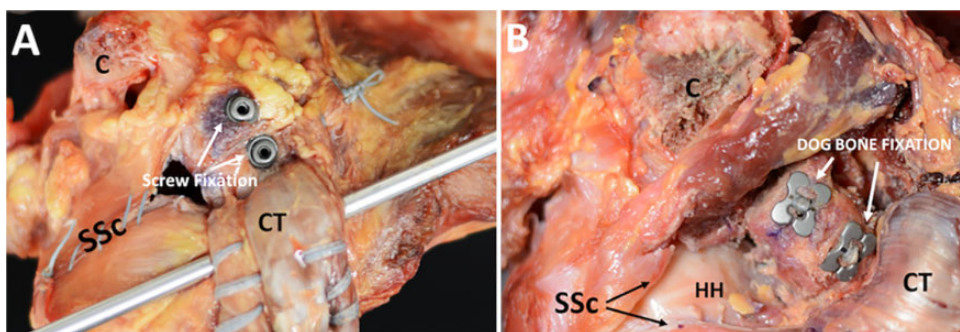


Figure 1. (A) Anterior view of fixation with 2 metal screws on a right shoulder. (B) Anterior view of suture button fixation on a right shoulder. C, coracoid; CT, conjoint tendon; HH, humeral head; SSc, subscapularis split.

introduced into the graft and to limit the differences in torque experienced by the graft between the 2 groups. For both groups, the subscapularis split was then repaired in a standard fashion using nonabsorbable sutures to model a standard Latarjet procedure.²²

After fixation of the specimens, the clavicle was disarticulated, and the surrounding soft tissues were removed to facilitate potting. Pins were used to fix the shoulder in 60° of abduction, relative to the medial border of the scapula, and 60° of external rotation, simulating a worst-case scenario during postoperative rehabilitation to coincide with previous biomechanical studies.^{15,16,19,23,32,33} Abduction and external rotation angles were measured with a goniometer by 2 observers (A.S.B, H.W.S.). External rotation was verified by the degree of rotation of the bicipital groove with respect to the neutral position. The scapular spine and body were then potted in poly(methyl methacrylate) (PMMA; Fricke Dental International) such that the fixed humerus was oriented vertically. The distal border of the subscapularis was identified at its attachment to the humerus, and an oscillating saw was used to transect the humerus parallel to the fibers of the subscapularis at this border.

Mechanical Testing Protocol

The testing protocol for this study was modified from that of Martetschläger et al²¹ to simulate a more clinically relevant testing model through a subscapularis split (Figure 2). The potted shoulder was rigidly fixed using table clamps after being positioned in the tensile testing machine (ElectroPuls E10000; Instron) to achieve a physiological line of pull along the conjoint tendon, parallel to the shaft of the humerus. In an attempt to strengthen the musculotendinous junction, the conjoint tendon was whipstitched on its medial and lateral borders using surgical tape (FiberTape; Arthrex) to reinforce the tissue and decrease the likelihood of any intrasubstance tears of the conjoint tendon and muscle.

To simulate the *in vivo* tension induced on the conjoint tendon by the subscapularis tendon in a clinical setting, a 5 mm-diameter, 42 cm-long high-strength 7075 aluminum bar was mounted in line with the fibers of the subscapularis tendon and positioned posterior to the conjoint tendon at the inferior portion of the subscapularis split, inferior to the




Figure 2. Biomechanical testing setup of a right shoulder with screw fixation. The potted scapular spine and body were rigidly clamped to the testing table. The conjoint tendon was whipstitched on its medial and lateral borders and gripped by a soft tissue clamp. The humerus was fixed at 60° of abduction and 60° of external rotation using beath pins. The humerus was then transected at the most inferior border of the subscapularis tendon. A 5 mm-diameter metal bar was placed in line with the fibers of the subscapularis tendon and positioned at the inferior edge of the bone block. The conjoint tendon was pulled vertically by the actuator to simulate physiological conditions until failure. For photographic purposes, the subscapularis split was not fully repaired to allow the intact bone block to be visualized. CG, coracoid graft; CT, conjoint tendon; HH, humeral head; SSc, subscapularis split.

edge of the coracoid graft. The actuator of the tensile testing machine was lowered to its minimum viable point before contacting the humerus, and the conjoint tendon was secured in the custom clamp. For each shoulder, the gauge length of the conjoint tendon was determined by measuring the distance between the inferior edge of the coracoid graft and the clamp interface using a dial caliper (Fowler).

Specimens were cyclically preconditioned from 2 to 10 N at 0.1 Hz for 10 cycles. After preconditioning, specimens

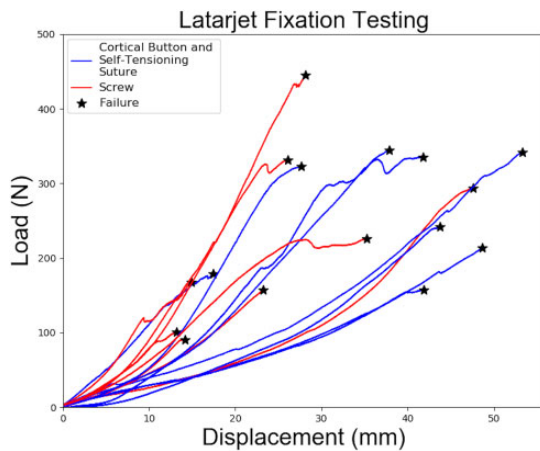


Figure 3. Force versus displacement curves for each tested specimen: screw fixation (red) and suture button fixation (blue).

were pulled to failure at a normalized displacement rate of 400% of the measured gauge length per minute. Failure load (yield load) was classified and detected algorithmically, post hoc, via a custom script (Python 3.4; Python Software Foundation),²⁹ as the maximum load value that preceded a $\geq 5\%$ drop-off from the local instantaneous peak load. Failure strain (%) was calculated as the displacement at failure divided by the gauge length and then multiplied by 100. The failure mechanism and location were recorded.

Statistical Analysis

Summary statistics are reported in terms of mean \pm SD with range and 95% CI. Paired *t* tests were used to determine significance ($P < .05$) between the screw and the suture button construct tests in paired specimens. All analyses, statistics, and graphics were produced using software written in Python 3.4.²⁶ To compare ultimate failure loads between screw and suture button fixation, 8 pairs of shoulders were sufficient to detect an effect size of $d = 1.2$ with 80% statistical power.

RESULTS

Mechanical Properties

Force versus displacement curves for each specimen are shown in Figure 3. The mean failure load (yield load) for screw fixation was 226 ± 114 N (range, 90-442 N; 95% CI, 147-305 N), compared with 266 ± 73 N (range, 157-341 N; 95% CI, 216-317 N) for suture button fixation (Figure 4, A and B). There was no significant difference in failure load between the 2 groups ($P = .257$). The mean strain at failure for screw fixation was $63\% \pm 21\%$ (range, 34%-99%; 95% CI, 48%-77%) of the measured gauge length, compared with $86\% \pm 26\%$ (range, 46%-119%; 95% CI, 69%-104%) of the measured gauge length for suture button

fixation (Figure 4, C and D). There was no significant difference in strain at failure between the 2 groups ($P = .060$).

Failure Method/Location

The distribution of the different failure mechanisms for the screw and suture button fixation groups is shown in Table 1, and the mechanisms of failure for each specimen are shown in Table 2. Three different failure mechanisms were observed in the study: failure at the bone block due to a vertical split between the 2 drill holes, intramuscular failure at the clamp-muscle interface, and failure at the tendon-bone interface.

DISCUSSION

The most important finding of this study was that there was no significant difference in ultimate load to failure between the screw and suture button fixation groups. The most common mode of failure for the screw fixation method was at the bone block drill holes, while an intramuscular rupture at the clamp-muscle interface occurred for the suture button construct. This information will help to guide clinical decision making for the fixation technique during the Latarjet procedure, given previous reports that metal screws, the traditional standard for Latarjet fixation, have been a significant cause of intraoperative and postoperative complications.^{5,6,8,12,28,35} We believe that the differing primary failure modes observed in this study indicate that the suture button technique should be further evaluated with clinical studies.

Recent clinical studies and reviews have reported a 30% rate of complications and 7% rate of reoperations after the Latarjet procedure, with the most common type of complication arising from graft nonunion, fibrous union, or postoperative graft migration in 10.1% of cases and symptomatic hardware in 6.5% of cases.^{8,12} The suture button fixation technique is inherently more difficult than the screw fixation technique, and it has been described that the learning curve to optimize operative time is 30 cases. However, the implementation of this technique has been reported to reduce intraoperative complications to as low as 3.3% and postoperative complications to 6.8% in a series of 88 cases.⁷ In a recent prospective clinical and computed tomography study of 76 patients,⁵ the authors reported that these complications were avoided and reported similar union rates of 91% with fixation using a suture button construct, a fixation method similar to that evaluated in this biomechanical study. This report⁵ suggests that implant-related complications may be mitigated with the use of a suture button construct, which has a comparable biomechanical profile with our study.

Our study tested a clinically relevant model by simulating a subscapularis split, using a metal rod to mimic the effect of the repaired and functional subscapularis to more accurately replicate an in vivo scenario. Clinically, the joint tendon becomes tethered by the subscapularis and ultimately redirects contraction forces in a nonlinear fashion, effectively reducing direct anterior or inferior forces

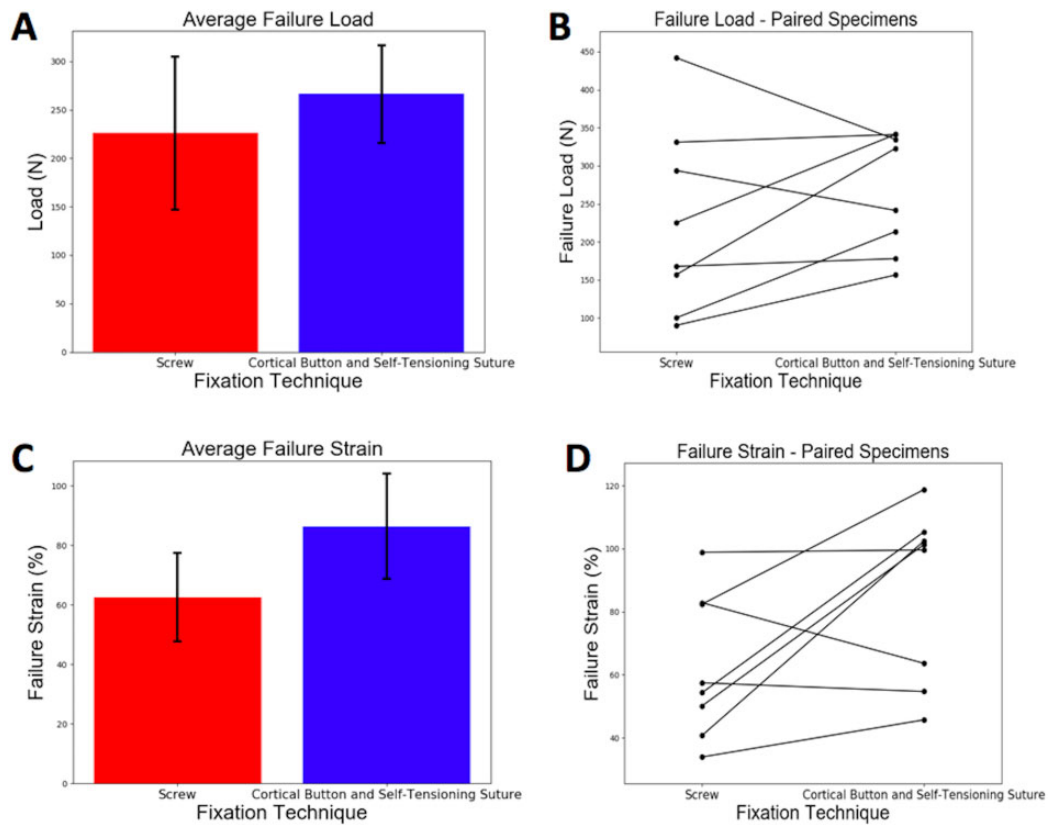


Figure 4. (A) Mean failure load (N) of screw fixation and suture button fixation with the respective 95% CI shown. (B) Failure loads for paired shoulder specimens. (C) Mean strain at failure (%) of screw fixation and suture button fixation with the respective 95% CI shown. (D) Failure strains for paired shoulder specimens.

TABLE 1
Mechanisms of Failure for Screw Fixation and Suture Button Fixation

Location	Screw, n	Suture Button, n
Bone interface	5	3
Clamp interface	2	5
Intramuscular	1	0

experienced on the bone block. The rationale for this testing model is that postoperatively, the glenohumeral joint is usually immobilized in neutral rotation for at least 2 weeks, limiting anterior humeral head translation in the early rehabilitation phases,^{5,24} leaving the conjoint tendon as the main force acting on the coracoid bone graft.²⁴

In this study, similar ultimate load-to-failure values in the screw and suture button fixation groups were found (226 N and 266 N, respectively). Although numerous studies have reported on the biomechanical properties of bone block fixation,^{1,11,24,29,30} different testing protocols have been utilized. Our study results can only be compared with the studies that tested fixation by pulling through the conjoint tendon. In this regard, our results are comparable with 2 studies that evaluated the ultimate load to failure

TABLE 2
Mechanisms of Failure for Each Specimen

Specimen	Specimen		Screw	Suture Button
	Age, y			
Pair 1	35	Bone screw interface	Bone button interface	
Pair 2	35	Intramuscular	Clamp interface	
Pair 3	62	Clamp interface	Bone button interface	
Pair 4	63	Bone screw interface	Bone button interface	
Pair 5	68	Bone screw interface	Clamp interface	
Pair 6	56	Bone screw interface	Clamp interface	
Pair 7	52	Clamp interface	Clamp interface	
Pair 8	50	Bone screw interface	Clamp interface	

of the classic Latarjet technique with metal screw fixation.^{24,30} Weppe et al³⁰ reported a median failure load of 202 N using 2 bicortical malleolar screws, while Montgomery et al²⁴ reported a mean failure load of 303 N using noncannulated screws. Discrepancies between our results and the previous literature can be explained by the

differences in testing models. In the study by Weppe et al,³⁰ the conjoint tendon was pulled parallel to the screw fixation site, while Montgomery et al²⁴ pulled in a directly inferior manner (perpendicular to the screw fixation site). Several other studies have evaluated the biomechanical strength of various fixation techniques for the Latarjet procedure.^{1,11,29} However, most of these studies assessed the effectiveness of reducing anterior shoulder instability by applying a medially directed force on the bone block,^{1,11,29} which is experienced clinically by anterior translation of the humeral head in later rehabilitation phases.^{1,11,24,29,32,33}

The majority of failures for the screw fixation group occurred from a fracture of the coracoid bone block (n = 5), while a majority of failures for the suture button fixation group occurred at the clamp-muscle interface (n = 5). In comparison, previous studies have reported that 90% to 100% of failures resulted from a fracture through one or both drill holes.^{24,30} A potential explanation for this discrepancy is that the screw fixation technique weakens the bone block by the creation of stress risers to a larger degree than the suture button construct because the two 3.75-mm holes required for screw passage are larger in the coracoid than the two 3-mm holes needed for the suture button construct; also, the suture button construct results in less rigidity at the articulating point of fixation, allowing for greater micromotion at this point before failure of the construct.

Limitations

We acknowledge some limitations to this study that are inherent to any cadaveric study. First, the mean age of the specimens used was 55.1 years. Clinically, anterior shoulder stabilization procedures are normally performed in younger male patients.^{4,13,22,25} Bone quality may have influenced load to failure because it has been shown that bone density decreases over time.³ We tried to mitigate this limitation by using paired male shoulders so that both fixation techniques were applied to specimens of similar bone quality. In addition, failure of the suture button construct would probably occur at higher loads than seen in this study because most failures occurred at the clamp-muscle interface rather than at the glenoid. Furthermore, the biomechanical properties of the bone graft were tested at time zero, where osseous healing over time cannot be reproduced with a cadaveric study. Also, the in vivo effect of the subscapularis split cannot be physiologically reproduced in cadaveric specimens, although we attempted to best simulate this property by using a method to semirigidly support the conjoint tendon in a position that attempts to reproduce the effect of the repaired subscapularis. During suture button fixation, we did not inspect the spinoglenoid notch, where an injury to the suprascapular nerve is possible. Clinically, physicians should be aware of the proximity of the suprascapular nerve when performing this technique. Our study also did not investigate translation of the humeral head and rotational control of the graft with the suture button construct. Future studies should investigate the effects of humeral head loading of the coracoid graft with fixation using the suture button construct.

CONCLUSION

The screw and suture button fixation techniques exhibited comparable biomechanical strength for coracoid bone block fixation of the Latarjet procedure. The most common mode of failure for the screw fixation method was at the bone block drill holes, while an intramuscular rupture at the clamp-muscle interface occurred for the suture button construct.

REFERENCES

- Alvi HM, Monroe EJ, Muriuki M, Verma RN, Marra G, Saltzman MD. Latarjet fixation: a cadaveric biomechanical study evaluating cortical and cannulated screw fixation. *Orthop J Sports Med.* 2016;4(4):2325967116643533.
- An VVG, Sivakumar BS, Phan K, Trantalis J. A systematic review and meta-analysis of clinical and patient-reported outcomes following two procedures for recurrent traumatic anterior instability of the shoulder: Latarjet procedure vs. Bankart repair. *J Shoulder Elbow Surg.* 2016;25(5):853-863.
- Beranger JS, Maqdes A, Pujol N, Desmoineaux P, Beaufils P. Bone mineral density of the coracoid process decreases with age. *Knee Surg Sports Traumatol Arthrosc.* 2016;24(2):502-506.
- Bessiere C, Trojani C, Pélégri C, Carles M, Boileau P. Coracoid bone block versus arthroscopic Bankart repair: a comparative paired study with 5-year follow-up. *Orthop Traumatol Surg Res.* 2013;99(2):123-130.
- Boileau P, Gendre P, Baba M, et al. A guided surgical approach and novel fixation method for arthroscopic Latarjet. *J Shoulder Elbow Surg.* 2016;25(1):78-89.
- Boileau P, Thélou C-É, Mercier N, et al. Arthroscopic Bristow-Latarjet combined with Bankart repair restores shoulder stability in patients with glenoid bone loss. *Clin Orthop Relat Res.* 2014;472(8):2413-2424.
- Bonneville N, Thélou CE, Bouju Y, et al. Arthroscopic Latarjet procedure with double-button fixation: short-term complications and learning curve analysis. *J Shoulder Elbow Surg.* 2018;27(6):e189-e195.
- Butt U, Charalambous CP. Complications associated with open coracoid transfer procedures for shoulder instability. *J Shoulder Elbow Surg.* 2012;21(8):1110-1119.
- Gartsman GM, Waggenspack WN, O'Connor DP, Elkousy HA, Edwards TB. Immediate and early complications of the open Latarjet procedure: a retrospective review of a large consecutive case series. *J Shoulder Elbow Surg.* 2017;26(1):68-72.
- Gendre P, Thélou C-E, d'Ollonne T, Trojani C, Gonzalez J-F, Boileau P. Coracoid bone block fixation with cortical buttons: an alternative to screw fixation? *Orthop Traumatol Surg Res.* 2016;102(8):983-987.
- Giles JW, Boons HW, Elkinson I, et al. Does the dynamic sling effect of the Latarjet procedure improve shoulder stability? A biomechanical evaluation. *J Shoulder Elbow Surg.* 2013;22(6):821-827.
- Griesser MJ, Harris JD, McCoy BW, et al. Complications and re-operations after Bristow-Latarjet shoulder stabilization: a systematic review. *J Shoulder Elbow Surg.* 2013;22(2):286-292.
- Hovelius L, Olofsson A, Sandström B, et al. Nonoperative treatment of primary anterior shoulder dislocation in patients forty years of age and younger: a prospective twenty-five-year follow-up. *J Bone Joint Surg Am.* 2008;90(5):945-952.
- Hovelius L, Sandström B, Olofsson A, Svensson O, Rahme H. The effect of capsular repair, bone block healing, and position on the results of the Bristow-Latarjet procedure (study III): long-term follow-up in 319 shoulders. *J Shoulder Elbow Surg.* 2012;21(5):647-660.
- Itoi E, Lee SB, Berglund LJ, Berge LL, An KN. The effect of a glenoid defect on anteroinferior stability of the shoulder after Bankart repair: a cadaveric study. *J Bone Joint Surg Am.* 2000;82(1):35-46.

16. Kleiner MT, Payne WB, McGarry MH, Tibone JE, Lee TQ. Biomechanical comparison of the Latarjet procedure with and without capsular repair. *Clin Orthop Surg*. 2016;8(1):84-91.
17. Latarjet M. [Treatment of recurrent dislocation of the shoulder]. *Lyon Chir*. 1954;49(8):994-997.
18. LeBus GF, Chahla J, Sanchez G, et al. The Latarjet procedure at the National Football League Scouting Combine: an imaging and performance analysis. *Orthop J Sports Med*. 2017;5(9):23259-67117726045.
19. Lee SB, Kim KJ, O'Driscoll SW, Morrey BF, An KN. Dynamic glenohumeral stability provided by the rotator cuff muscles in the mid-range and end-range of motion: a study in cadavera. *J Bone Joint Surg Am*. 2000;82(6):849-857.
20. Longo UG, Loppini M, Rizzello G, Ciuffreda M, Maffulli N, Denaro V. Latarjet, Bristow, and Eden-Hybinette procedures for anterior shoulder dislocation: systematic review and quantitative synthesis of the literature. *Arthroscopy*. 2014;30(9):1184-1211.
21. Martetschläger F, Saier T, Weigert A, et al. Effect of coracoid drilling for acromioclavicular joint reconstruction techniques on coracoid fracture risk: a biomechanical study. *Arthroscopy*. 2016;32(6):982-987.
22. McHale KJ, Sanchez G, Lavery KP, et al. Latarjet technique for treatment of anterior shoulder instability with glenoid bone loss. *Arthrosc Tech*. 2017;6(3):e791-e799.
23. Mologne TS, Zhao K, Hongo M, Romeo AA, An K-N, Provencher MT. The addition of rotator interval closure after arthroscopic repair of either anterior or posterior shoulder instability: effect on glenohumeral translation and range of motion. *Am J Sports Med*. 2008;36(6):1123-1131.
24. Montgomery SR, Katthagen JC, Mikula JD, et al. Anatomic and biomechanical comparison of the classic and congruent-arc techniques of the Latarjet procedure. *Am J Sports Med*. 2017;45(6):1252-1260.
25. Owens BD, Duffey ML, Nelson BJ, DeBerardino TM, Taylor DC, Mountcastle SB. The incidence and characteristics of shoulder instability at the United States Military Academy. *Am J Sports Med*. 2007;35(7):1168-1173.
26. Python Software Foundation. Python: a programming language that lets you work quickly and integrate systems more effectively. <https://www.python.org/>. Accessed August, 2017.
27. Randelli P, Fossati C, Stoppani C, Evola FR, De Girolamo L. Open Latarjet versus arthroscopic Latarjet: clinical results and cost analysis. *Knee Surg Sports Traumatol Arthrosc*. 2016;24(2):526-532.
28. Shah AA, Butler RB, Romanowski J, Goel D, Karadagli D, Warner JJP. Short-term complications of the Latarjet procedure. *J Bone Joint Surg Am*. 2012;94(6):495-501.
29. Shin JJ, Hamamoto JT, Leroux TS, et al. Biomechanical analysis of Latarjet screw fixation: comparison of screw types and fixation methods. *Arthroscopy*. 2017;33(9):1646-1653.
30. Weppe F, Magnussen RA, Lustig S, Demey G, Neyret P, Servien E. A biomechanical evaluation of bicortical metal screw fixation versus absorbable interference screw fixation after coracoid transfer for anterior shoulder instability. *Arthroscopy*. 2011;27(10):1358-1363.
31. Willemot LB, Wodicka R, Bosworth A, Castagna A, Burns J, Verborgt O. Influence of screw type and length on fixation of anterior glenoid bone grafts. *Shoulder Elbow*. 2018;10(1):32-39.
32. Yamamoto N, Muraki T, An K-N, et al. The stabilizing mechanism of the Latarjet procedure: a cadaveric study. *J Bone Joint Surg Am*. 2013;95(15):1390-1397.
33. Yamamoto N, Muraki T, Sperling JW, et al. Stabilizing mechanism in bone-grafting of a large glenoid defect. *J Bone Joint Surg Am*. 2010;92(11):2059-2066.
34. Zhu Y-M, Jiang C, Song G, Lu Y, Li F. Arthroscopic Latarjet procedure with anterior capsular reconstruction: clinical outcome and radiologic evaluation with a minimum 2-year follow-up. *Arthroscopy*. 2017;33(12):2128-2135.
35. Zuckerman JD, Matsen FA. Complications about the glenohumeral joint related to the use of screws and staples. *J Bone Joint Surg Am*. 1984;66(2):175-180.